FETAL SKULL

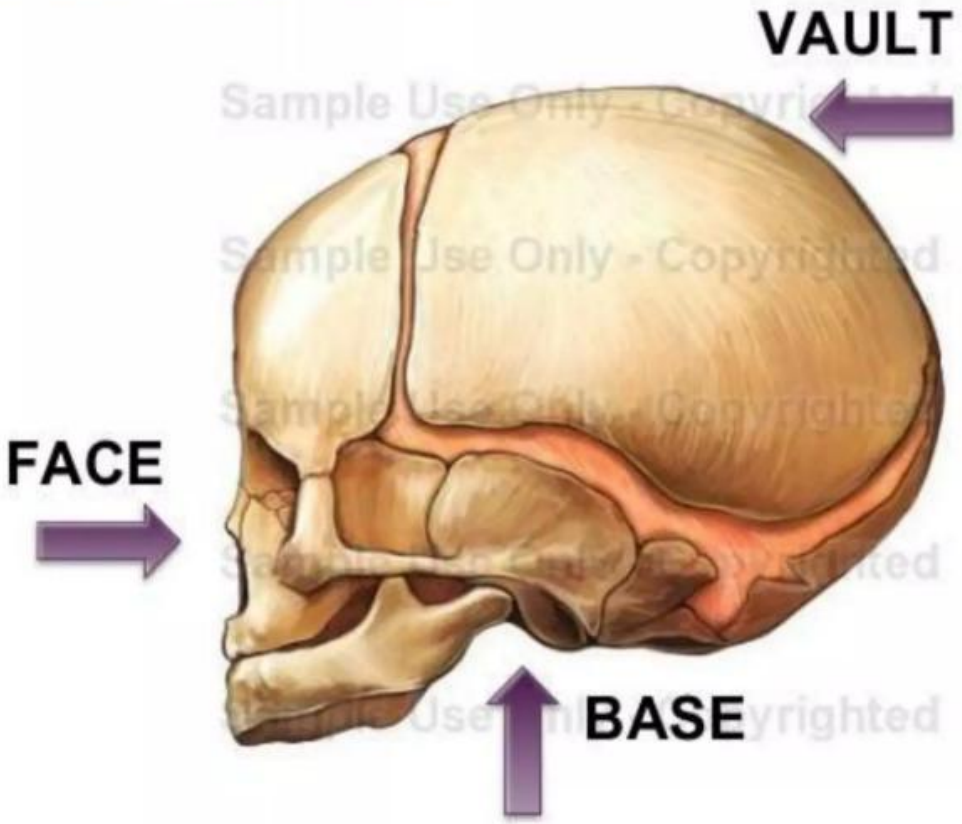

VERTEX

It is a quadrangular area bounded anteriorly by the bregma and coronal suture behind by the lambda and lambdoidal sutures and laterally by lines passing through the parietal eminences.

BROW

It is an area bounded on one side by the anterior fontanelle and coronal sutures and on the other side by the root of the nose and supra-orbital ridges of either side.

FACE

It is the area bounded by the root of the nose and supra-orbital ridges and on the other, by the junction of the floor of the mouth with neck.

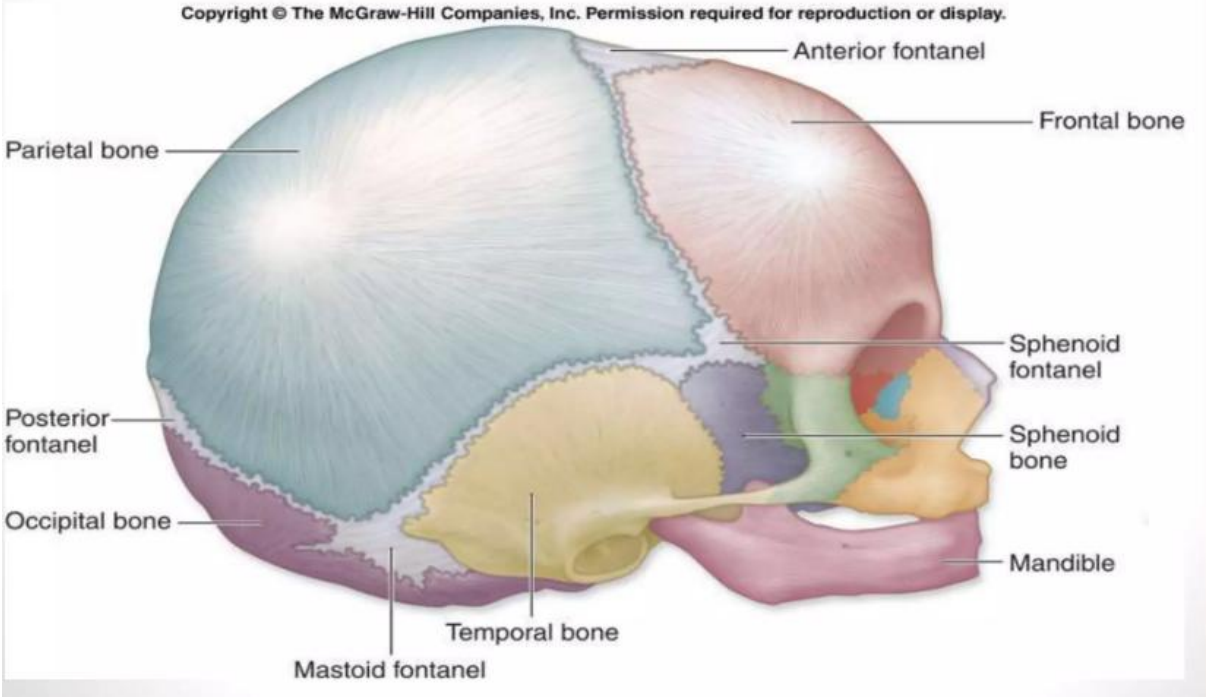

SINCIPUT

It is the area lying in front of the anterior fontanelle and corresponds to the area of brow.

OCCIPUT

It is the area limited to the occipital bone.

SUTURES

Flat bones of the vault are united together by the non-osssified membranes attached to the margins of the bones. These are called **sutures.**

❖THE SAGGITAL SUTURE:

Lies b/w two parietal bones.

❖THE CORONAL SUTURES :

Run b/w parietal and frontal bones on either sides.

❖THE FRONTAL SUTURE :

Lies b/w two frontal bones.

❖THE LAMBDOIDAL SUTURES :

Separate the occiput bone and two parietal bones.

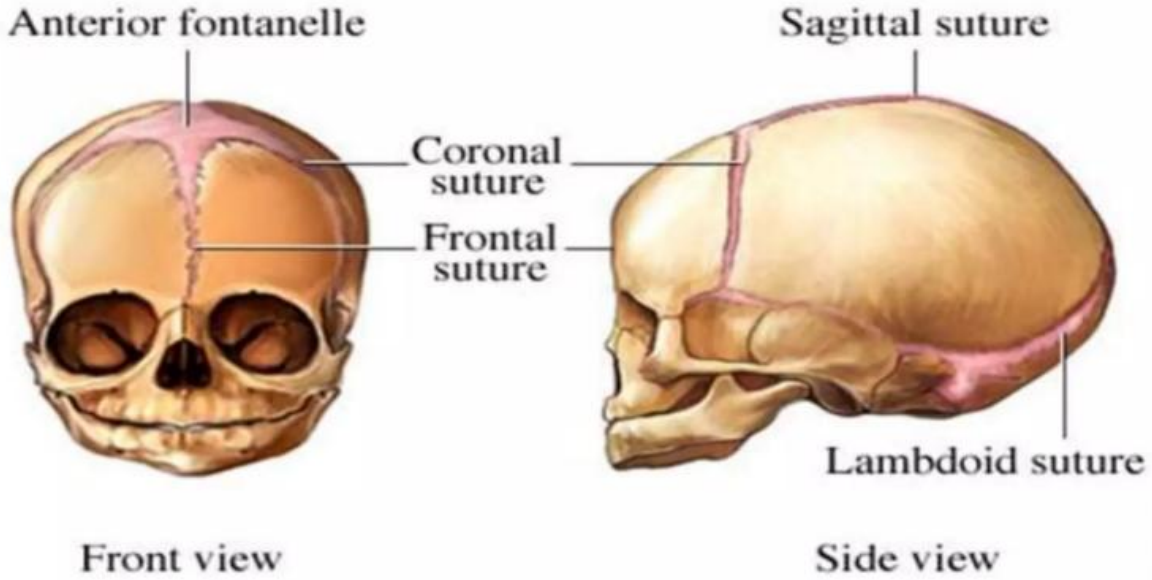

IMPORTANCE

- It permits gliding movement of one bone over the other during moulding of the head.
- Digital palpations of sagittal suture during internal examination in labour gives an idea of the manner of engagement of the head, degree of internal rotation of the head and degree of moulding of the head.

FONTANELLES

Wide gap in the suture line is called fontanelle.

ANTERIOR FONTANELLE:

- Formed by joining four sutures in midplane.
- Anteriorly frontal bone-.
- Posteriorly saggital.
- On either side coronal suture. Diamond like shape.
- Floor is made by a membrane.
- Ossified at 18months after birth.

IMPORTANCE

- Its palpation through internal examination denotes the degree of flexion of the head.
- It facilitates moulding of the head.
- As it remains membranous long after birth, it helps in accommodating the marked brain growth, the brain becoming almost double its size during first year of life.
- Palpation of the floor reflects intracranial status- depressed in dehydration, elevated in raised intracranial tension.
- Collection of blood and exchange transfusion, on rare occasion, can be performed through it via the superior longitudinal sinus.
- Cerebrospinal fluid can be drawn, although rare, through the lateral angle of the anterior fontanelle from the lateral ventricle.

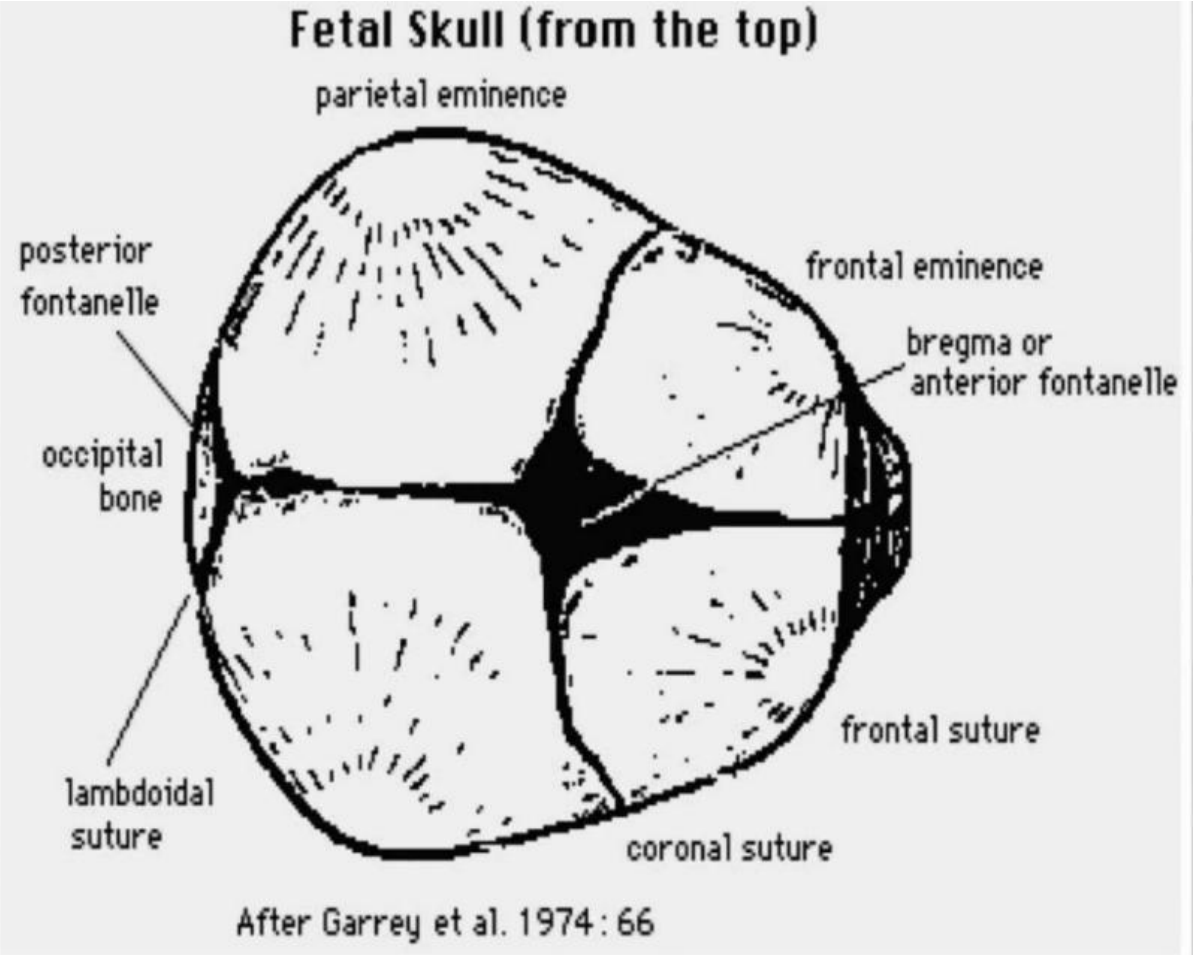

POSTERIOR FONTANELLE:

➢Formed by junction of three sutures.
❖Saggital suture anteriorly.
❖Lambdoidal suture on either side.

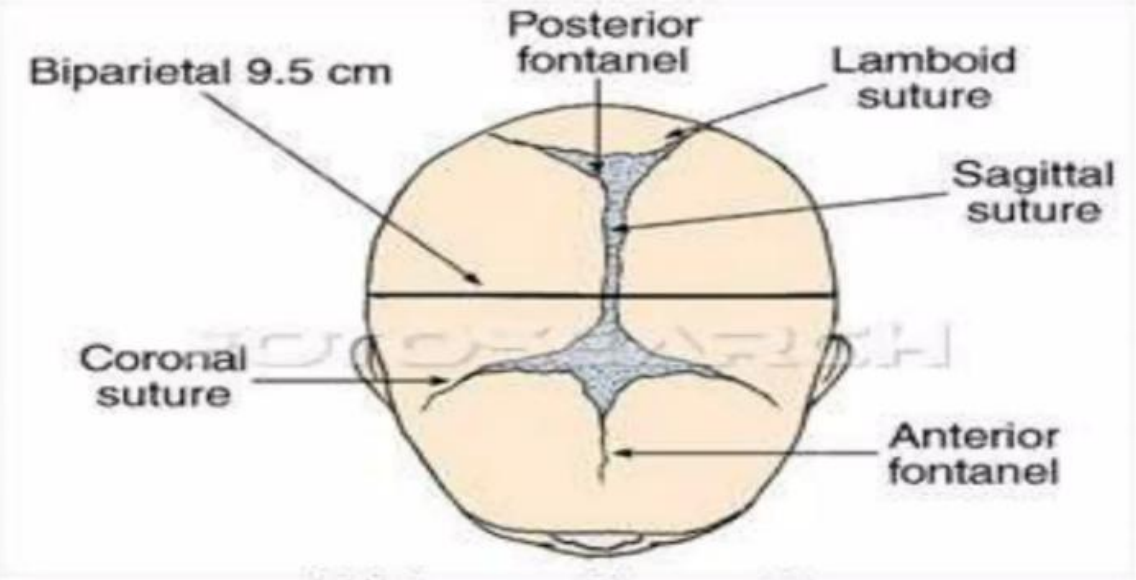

➢Triangular in shape.

➢Measure about 1.2 x1.2cm.

➢Its floor is membranous but become bony at 3months.

SAGGITAL FONTANELLE:-

➢ It is inconsistent in its presence. It is situated on the saggital suture at the junction of anterior to two-third and posterior one-third.

➢ It has got no clinical importance.

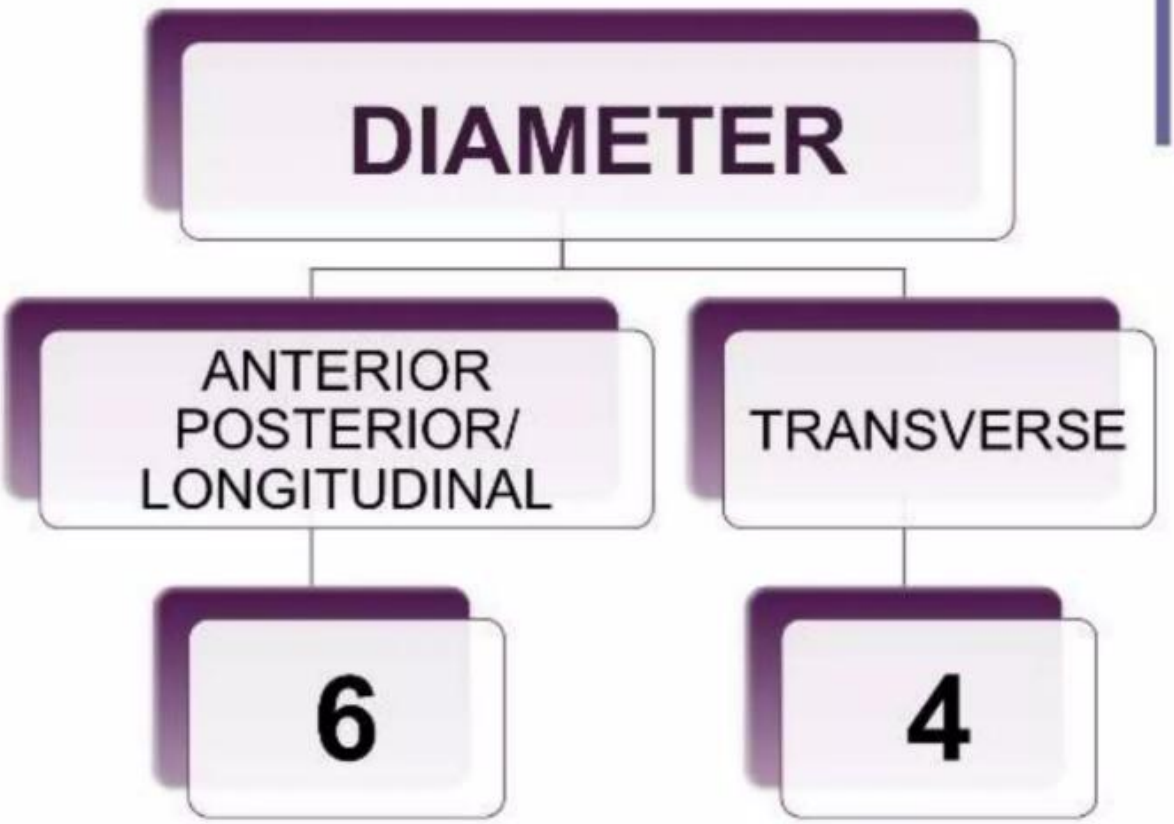

DIAMETER OF SKULL

TRANSVERSE DIAMETER:-

- **Bi parietal Diameter-**
  - Measure about 9.5cm.
  - It extends between two parietal eminences.

- **Bi-temporal diameter-**
  - Measure about 8cm.
  - It is the distance between anterio-inferior ends of the coronal suture.

LONGITUIDNAL DIAMETER

- **Sub-occipitobregmatic-** 9.5cm. The diameter from below the occipital protuberance to the center of the anterior fontanelle.
- **Sub-occipitofrontal-** 10cm. The diameter from below the occipital protuberance to the center of the frontal suture.
- **Occipitofrontal-**11.5cm. The diameter from the occipital protuberance to the glabella.

- **Mentovertical-**13.5cm. The diameter from the point of the chin to the highest point on the vertex, slightly nearer to the posterior than to the anterior fontanelle.

- **Submentovertical-**11.5cm. the diameter from the point where the chin joins the neck to the highest point where the chin joins the neck to the highest point on the vertex.

- **Submentobregmatic-**9.5cm. The diameter from the point where the chin joins the neck to the center of bregma.

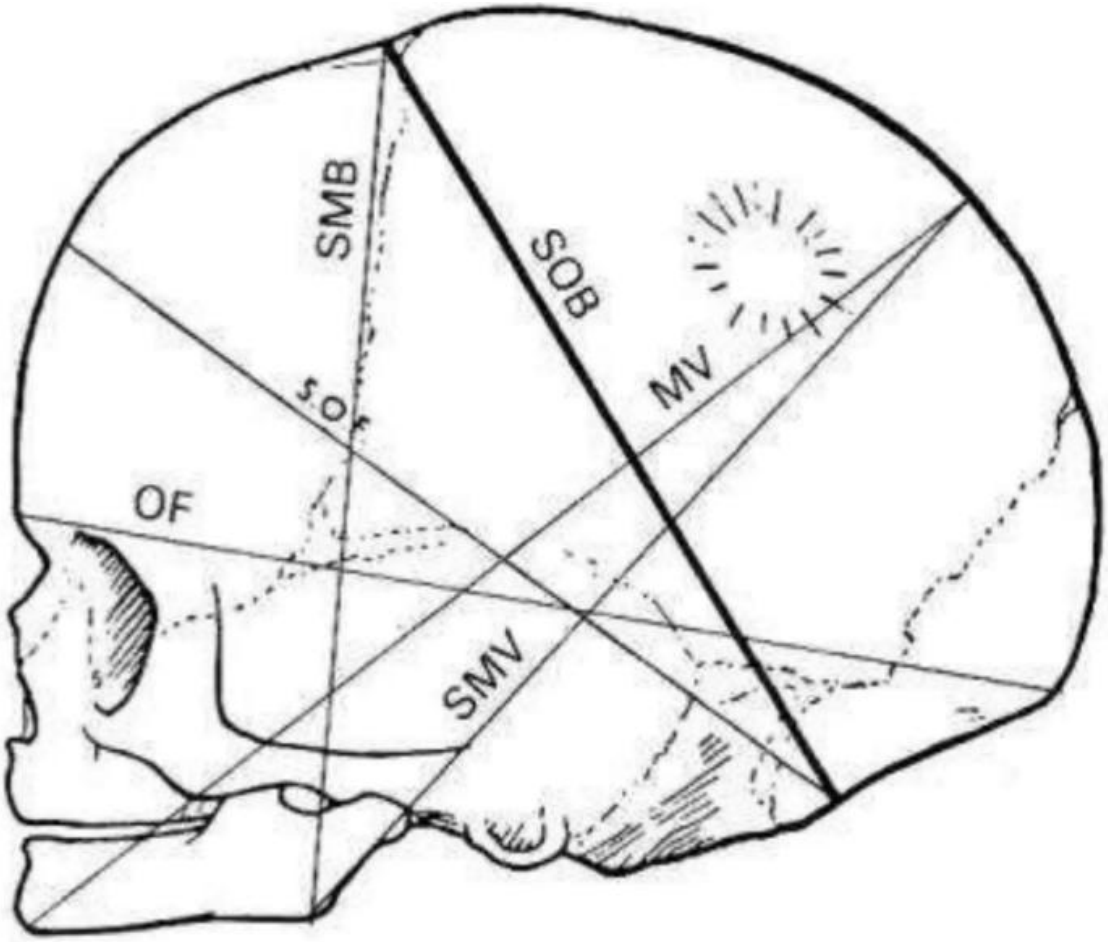
OF
SMB
S.O.
SMV
SOB
MV